

## SPONTANEOUS BILATERAL TUBAL PREGNANCY: A CASE REPORT

Anberbir Girma, MD<sup>1</sup>, Gudina Fikadu, MD<sup>2</sup>, Woubishet Girma, MD<sup>1</sup>

### ABSTRACT

**BACKGROUND:** Ectopic pregnancy is implantation outside the uterine cavity and its one of obstetrics emergency and it is among the common causes of maternal death in the first trimester of pregnancy. It complicates up to 2% of all pregnancies, but bilateral tubal pregnancies are among the rarest medical occurrence and its incidence 1 in 1580 to 1 in 200,000 pregnancies.

**CASE:** This is a case report of a 38-year-old woman who presented with lower abdominal pain and vaginal bleeding of 3 days. She had left sided unruptured tubal ectopic and right sided ruptured tubal ectopic pregnancy. Trans abdominal Ultrasonography revealed a 5 X 3cm left adnexal mass suggestive of ectopic pregnancy, uterine cavity was empty and free fluid was seen in the pelvis and paracolic gutter. The diagnosis of bilateral tubal ectopic was made intraoperatively. Bilateral salpingectomy was performed. Histopathology examination confirmed bilateral tubal ectopic pregnancy.

**CONCLUSION:** It is very important to carefully review both adnexa during sonographic evaluation and when exploratory laparotomy or laparoscopy is undertaken for ectopic pregnancy.

**KEYWORDS:** Pregnancy, tubal, ectopic, bilateral, salpingectomy

(Ethiopian Journal of Reproductive Health; 2019; 11;3:59-62)

---

1 Department of Gynecology and Obstetrics, Jimma University, Ethiopia

2 Department of Gynecology and Obstetrics, Gimbi Hospital, Ethiopia

## INTRODUCTION

Ectopic pregnancy is implantation outside the uterine cavity and its one of obstetrics emergency and among the common causes maternal death in the first trimester of pregnancy. It complicates up to 2% of all pregnancies, but bilateral tubal pregnancies are among the rarest medical occurrence and its incidence 1 in 1580 to 1 in 200,000 pregnancies<sup>1,16</sup>. Due to increasing incidence of pelvic infection the incidence of ectopic pregnancy is generally increasing. The risen incidence may it due to assisted reproductive technology or due to early detection of ectopic pregnancy with advanced scanning<sup>2-5</sup>. Even though exact cause of bilateral tubal

## CASE REPORT

A 38-year-old gravida II Para I mother who came to our hospital with complaint of lower abdominal pain and spotting vaginal bleeding of 3 days. She claims to be amenorrhic for the past three months. She was not on any type of contraception, no history of pelvic surgery, no history of STI treatment or symptoms. She is known HIV positive patient on highly active anti retro viral treatment. On examinations Pulse rate was 120 beats per minute and the other vital signs were normal, on the abdomen she had diffused abdominal tenderness.

Ultrasound was done and shows empty uterus, 5 x 3cm left adnexal echo-complex mass and free fluid in the pelvis and paracolic gutter.

With the diagnosis of ruptured ectopic pregnancy laparotomy was done and intra-operative finding was left side unruptured ampullary ectopic pregnancy with right side ruptured ampullary ectopic pregnancy and about 1200ml of haemoperitoneum. Haemoperitoneum sucked out and bilateral salpingectomy was done, the patient discharged on 5th post op day. Histopathology Section from both fallopian tubes shows multiple chorionic villas having capillaries with nucleated RBC, fetal tissues and hemorrhage admixed with areas of fibrinous inflammation and the conclusion was the Fallopian tube bilateral ectopic pregnancy.

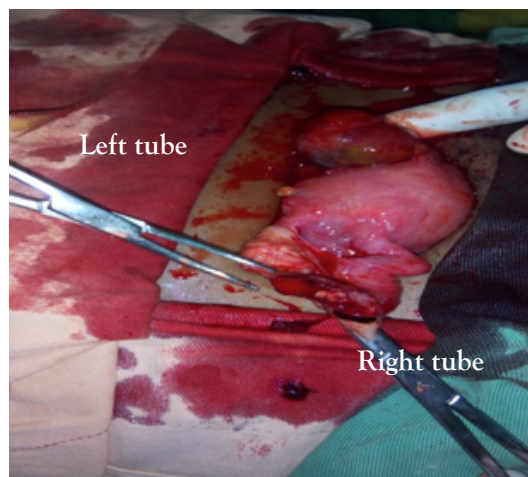


Figure 1: A picture taken intra-operatively

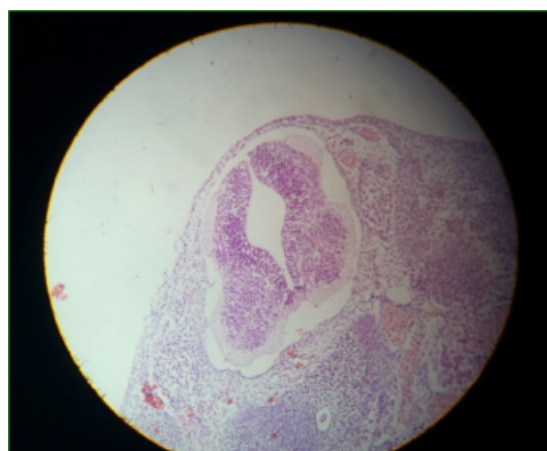


Fig2 Fetal tissue with neural plates

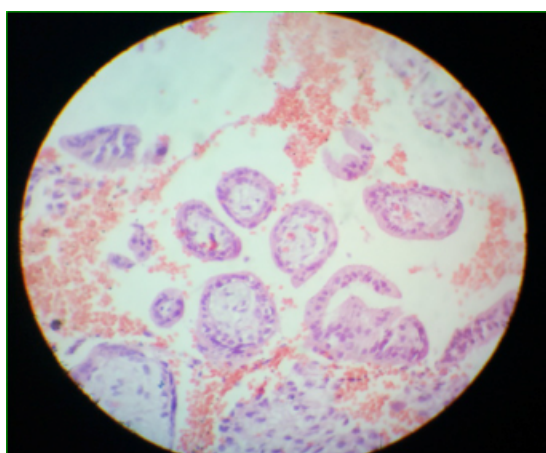


Fig3 Villi with fetal RBC

## DISCUSSION

The rarest form of ectopic pregnancy is bilateral tubal pregnancy, which occur spontaneously<sup>6</sup>. Two hundred case reports of bilateral tubal ectopic pregnancy have been observed in the literature, in which most cases occurred after using assisted reproductive technique<sup>6</sup>. In these cases there was no history of infertility treatment. We just found one published case report in Ethiopia<sup>17</sup>. Even though HIV infected patients have increased risk of ectopic pregnancy due to high prevalence of concomitant pelvic inflammatory disease, we could get only one published case report of bilateral tubal ectopic pregnancy in HIV infected patients.

Though tuboplasty and assisted reproductive technology have resulted in increased rates, sexually transmitted infections remain the most important risk factor. Still, many patients with ectopic pregnancy have no identifiable risk factors. It is also suggested that the larger cell mass of the fertilized twin zygote may result in retarded tubal transport with consequential tubal implantation. In our patient, there was no identified risk factor for ectopic pregnancy and for twinning.

Ectopic pregnancy remains a diagnostic challenge due to its varied clinical presentation and can result in significant morbidity and mortality. Transvaginal ultrasound is very effective in diagnosing an intrauterine pregnancy by 24 days post-ovulation with 90% sensitivity, 99.8% specificity, 93% positive predictive value and 99.8% negative predictive value<sup>7</sup>. In our case, the patient had a transabdominal ultrasound which identified 5 x 3cm left adnexal echo complex mass with free fluid in the cul-de-sac and paracolic gutter. Ultrasonography in our case failed to make a diagnosis of bilateral tubal pregnancy. In most cases of bilateral ectopic pregnancy, they failed to make a diagnosis based on ultrasonography and was made intra-operatively<sup>8,9,10</sup>. Al Quraanet. al and Brady et.al reported bilateral tubal ectopic pregnancy with one tube ruptured and the other intact<sup>10,11</sup>.

In this case the right tube had ruptured, the left tube was distended, ecchymotic and easily bleeding upon touching so that we were not able to save tube. Final bilateral salpingectomy was done. Comprehensive clinical guidelines for the treatment of ectopic pregnancy have

been published by the Royal College of Obstetricians & Gynecologists<sup>14</sup>. Because of its rarity, synchronous ectopic pregnancy is not covered, but the principles of treatment can still be applied. Laparoscopic surgical treatment is preferred to open surgery, because the patient recovers more quickly and subsequent rates of intrauterine and ectopic pregnancy are similar<sup>15</sup>. Our patient, because of acute symptoms and extensive blood in the pelvis was not suitable for either laparoscopic surgery or medical management with methotrexate. Therefore, exploratory laparotomy was performed.

It is very important to identify and close examination of both adnexa when exploratory laparotomy or laparoscopy is undertaken for ectopic pregnancy.

## CONCLUSION

Even though it is rare, bilateral ectopic pregnancy should be considered in all patients with ectopic pregnancy, and contralateral adnexa has to be examined during sonographic evaluation, laparoscopy or laparotomy.

## CORRESPONDING AUTHOR:

Anberbir Girma

Department of Gynecology and Obstetrics, Jimma University, Jimma, Ethiopia

Email: girmaanberbir@yahoo.com

## REFERENCES

1. A. L. Awwad, Mona M., A.L. Daham, Nora, Esset, John S. Spontaneous un-ruptured bilateral ectopic pregnancy: conservative tubal surgery. *Obstetrical and Gynecological Survey*. 54(9):543-544, 1991.
2. Health Canada. Canadian Perinatal Health Report, 2003. Ottawa: Minister of Public Works and Government Services Canada, 2003.
3. Current Trends Ectopic Pregnancy - United States, 1990-1992. *MMWR* 1995, Jan 27; 44(03):46-8.
4. Rock JA, Howard WJ. Ectopic Pregnancy. In: Te linde's Operative Gynecology, 9th Edition. Philadelphia: Lippincott, Williams and Wilkins; 2003: 507-36.
5. Summer FM, Reisenberger K, Bogner G, Nagele F. laparoscopic management of an unrecognized spontaneous bilateral tubal pregnancy. *Acta ObstetGynecol Scand* 2002; 81:366-8.
6. Othman M, Karali S, Badawi K, Mossa H. Bilateral ectopic pregnancy: case report. *Webmed Central Obstetrics and Gynecology*. 2013; 4:WMC004354.
7. Condous G, Kirk E, Lu C, Van Huffel S, Gevaert O, De Moor B et al. Diagnostic accuracy of varying discriminatory zones for the prediction of ectopic pregnancy in women with a pregnancy of unknown location. *Ultrasound ObstetGynecol* 2005; 26: 770-5.
8. Othman M, Karali S, Badawi K, Mossa H. Bilateral ectopic pregnancy: case report. *Webmed Central Obstetrics and Gynecology*. 2013; 4:WMC004354.
9. Campo S, Campo V, Gambadauro P. Bilateral tubal pregnancy following in vitro fertilization and embryo transfer. *Eur J ObstetGynecol Reprod Biol*. 2003; 110:237-9. doi: 10.1016/S0301-2115(03)00103-9. PubMed PMID: 12969592.
10. Al-Quraan GA, Al-Taani MI, Nusair BM, El-Masri A, Arafat MR, Khateeb MM. Spontaneous ruptured and intact bilateral tubal ectopic pregnancy. *East Mediterr Health J*. 2007; 13:972-4. PubMed PMID: 17955781.
11. Brady J, Wilson M. Spontaneous bilateral tubal ectopic pregnancy. *J R Soc Med*. 2005; 98:120-1. doi: 10.1258/jrsm.98.3.120. PubMed PMID: 15738557; PubMed Central PMCID: PMC1079415.
12. Foster HM, Lakshin AS, Taylor WF. Bilateral tubal pregnancy with vaginal delivery. *ObstetGynecol* 1982; 60:664-6.
13. Tabachonikoff RM, Dada MO, Woods RJ, Rohere D, Myers CP. Bilateral tubal pregnancy. A report of an unusual case. *J Reprod Med* 1998;43:707
14. Kelly AJ, Sowter MC, Trmder J. *The Management of Tubal Pregnancy*. Loudon: RCOG Press, 2004
15. HajcnusPj, Mol BWJ, Bossuyt PMM, Ankum WM, Van derVccnF. Interventions for tubal ectopic pregnancy. *Cochrane Database of Systematic Reviews* 2000, Issue 1
16. S. Hofmann, H. Abele and C. Bachmann: Spontaneous bilateral ectopic pregnancy: incidental finding during laparoscopy
17. Muhidin Abdo Banko, spontaneous bilateral ampullary tubal ectopic pregnancy in an ethiopian woman: case report